

## Comments and illustrations of the WFUMB CEUS liver guidelines: rare congenital vascular pathology

Kathleen Möller<sup>1</sup>, Theresa Tschu<sup>2</sup>, Chiara de Molo<sup>3</sup>, Carla Serra<sup>3</sup>, Xin Wu Cui<sup>4</sup>, Yi Dong<sup>5</sup>, Michael Hocke<sup>6</sup>, Adrian Lim<sup>7</sup>, Ehsan Safai Zadeh<sup>8</sup>, Christian Görg<sup>8</sup>, David Srivastava<sup>2</sup>, Stephan Henning<sup>9</sup>, Christian Jenssen<sup>10,11</sup>, Annalisa Berzigotti<sup>12</sup>, Michael Jung<sup>13</sup>, Christoph F Dietrich<sup>2</sup>

<sup>1</sup>Medical Department I/Gastroenterology, SANA Hospital Lichtenberg, Berlin, Germany, <sup>2</sup>Department Allgemeine Innere Medizin der Kliniken (DAIM) Hirslanden Beau Site, Salem und Permanence, Bern, Switzerland, <sup>3</sup>Interventional, Diagnostic and Therapeutic Ultrasound Unit, Department of Medical and Surgical Sciences, IRCCS, Azienda Ospedaliero-Universitaria Sant'Orsola Malpighi Hospital, Bologna, Italy, <sup>4</sup>Department of Medical Ultrasound, Tongji Hospital, Tongji Medical College, Huazhong University of Science and Technology, Wuhan, <sup>5</sup>Department of Ultrasound, Xinhua Hospital Affiliated to Shanghai Jiaotong University School of Medicine, Shanghai, China, <sup>6</sup>Medical Department, Helios Klinikum Meiningen, Germany, <sup>7</sup>Imaging Department, Imperial College Healthcare NHS Trust, Charing Cross Hospital, Fulham Palace Road, London, UK, <sup>8</sup>Interdisciplinary Center of Ultrasound Diagnostics, University Hospital Giessen and Marburg, Philipps University Marburg, Marburg, Germany, <sup>9</sup>Clinic for Pediatrics/ Gastroenterology, Nephrology and Metabolic Medicine, Charité – University Medicine Berlin, Campus Virchow Clinic, Germany, <sup>10</sup>Krankenhaus Märkisch-Oderland, Department of Internal Medicine, Strausberg, Germany; <sup>11</sup>Brandenburg Institute for Clinical Ultrasound (BICUS) at Medical University Brandenburg, Neuruppin, Germany, <sup>12</sup>Department of Visceral Surgery and Medicine, Inselspital, Bern University Hospital, University of Bern, Switzerland, <sup>13</sup>Department of Radiology, University Medical Center Regensburg, Regensburg, Germany

### Abstract

In this overview of vascular changes of the liver, variations in the liver vessels are discussed, in addition to congenital malformations such as Abernethy malformation, patent ductus venosus Arantii and hereditary hemorrhagic telangiectasia (Osler-Weber-Rendu disease). Particular attention is paid to focal liver lesions, especially focal nodular hyperplasia (FNH), but also other solid tumours that develop as a result of altered liver vascularisation. The article focuses on the ultrasonic appearances and changes of the liver, depicted in B-mode sonography, Doppler studies and in contrast-enhanced ultrasonography (CEUS). The clinical manifestations of these conditions associated with other organ systems are also highlighted.

**Keywords:** Abernethy malformation, patent ductus venosus Arantii, hereditary hemorrhagic telangiectasia, ultrasonography, contrast-enhanced ultrasound

### Introduction

The World Federation for Ultrasound in Medicine and Biology (WFUMB) has published guidelines on the use of contrast-enhanced ultrasound (CEUS) for the

evaluation of focal liver lesions [1-5]. Improved detection and characterization of common focal liver lesions (FLL) are the main topics of these guidelines. In recent years, conventional ultrasound (US) and CEUS features of less common FLL have been described in detail.

In a series of publications initiated by this review on vascular malformations, we aim to summarize the US and CEUS features of very rare FLL where there are limited reports and figures published in order to create a library of these rare lesions.

The hepatic vessels may show a variety of variations; many of which will have no clinical significance. How-

Received 11.07.2022 Accepted 25.08.2022

Med Ultrason

2022, Vol. 24, No 4, 461-472

Corresponding author: Prof. Dr. med. Christoph F. Dietrich, MBA  
Department Allgemeine Innere Medizin (DAIM)  
Kliniken Beau Site, Salem und Permanence,  
Hirslanden, Bern  
CH-3036 Bern, Schweiz

ever, there are changes in the hepatic vessels that appear confusing initially and others which require an extremely good knowledge and a trained eye to recognize. Portal venous vascular malformations such as Abernethy malformation, patent ductus venosus, and hereditary hemorrhagic telangiectasia (HHT), also known as Osler-Weber-Rendu disease with arteriosystemic and arterioportal shunts not only cause fibrosis of the liver parenchyma and portal hypertension, but also have systemic implications. These clinical pictures may be equally associated with other systemic abnormalities. Consequently, decreased portal venous flow leads to compensatory increased arterialization of the liver. Therefore, a hyperplastic reaction of the liver with formation of nodules may occur. The most common variant is focal nodular hyperplasia. However, other tumors are also possible. Differentiation of these tumors in a liver with decreased or absent portal venous flow, intrahepatic shunts, and fibrotic or cirrhotic liver parenchyma can be challenging.

In the following review, various vascular changes, variants and malformations are discussed.

### **Hepatic vascular malformations and variations**

Hepatic malformations must be distinguished from variations in the hepatic vasculature. Affecting up to one third of the population, variations of the liver vessels are common and diverse and can become clinically significant in terms of segmental assignment of focal liver lesions, for vascular interventions and in hepatobiliary surgery [6-9].

#### ***Variations in hepatic vascularization, variations in the umbilical veins***

A persistent right umbilical vein is considered an anomaly in development however, a malformation is also plausible. During fetal development, there are right and left umbilical veins. Typically, the right umbilical vein involutes, and the left remains present. A persistent right umbilical vein, however, communicates with the right portal vein and not with the left portal venous branch as in usual development. In the case of a persistent right umbilical vein, an assessment for congenital heart disease should be performed [10].

#### ***Variations in the portal vein system***

The most common anomaly is portal vein trifurcation, in which the main portal vein divides into three branches: the right anterior, right posterior, and left anterior portal veins. This is observed in about 7% of the population. Another variation is that the first branch of the main portal vein is the right posterior branch, followed by branches into the right anterior and left portal veins, noted in around 5% of the population. Other less

common variations include quadfurcation of the portal vein and origin of the segment-VIII or -IV branch from the main portal vein [6,10].

#### ***Hepatic artery variations***

The most common anomalies are a replaced or accessory right hepatic artery from the superior mesenteric artery (10% of cases) or a replaced or accessory left hepatic artery from the left gastric artery (approx. 10%). Other variations include an atypical origin of both the left and right hepatic arteries and the common hepatic artery arising from the superior mesenteric artery or directly from the aorta [9,10].

#### ***Hepatic vein variations***

Common anomalies here include double right hepatic vein, drainage of segment VIII into the middle hepatic vein or an accessory inferior right hepatic vein draining independently into the intrahepatic IVC, usually draining segment VI or VII and rarely segment V [7,10].

#### ***Malformations or congenital anomalies***

##### ***Preduodenal portal vein***

A preduodenal portal vein may be an incidental finding, although it is associated with duodenal obstruction in about 50% of all cases. Duodenal obstruction is rarely a direct result of the anomalous vein. Instead, it is more often caused by secondary associated duodenal stenosis and/or atresia, in association with malrotation, annular pancreas, or cases with heterotaxy (polysplenia) and biliary atresia. The aberrant vessel can also be identified with US and should be assessed in a patient with situs anomalies or biliary atresia [10].

##### ***Portal vein hypoplasia or atresia***

Hypoplasia or atresia of the portal vein may involve all or a portion of the portal vein. This raises the question, on the one hand of the difference between atresia or hyperplasia of the portal vein and, on the other hand, Abernethy malformation with a congenital portosystemic shunt and atresia or hyperplasia of the portal vein. One possible explanation is that in the case of excessive involution of the umbilical vein after birth, portal vein atresia and/or stenosis may develop [10,11]. The course for the development of Abernethy malformation is set during embryological development. Incomplete involution of the vitelline venous system in response to the development of hepatic sinusoids is probably the main reason for shunt formation [11]. Atresia of a major branch of the portal vein can be associated absence of the corresponding hepatic lobe. A hypoplastic portal vein is often as small as or smaller than the adjacent hepatic artery. A portal vein diameter of 3 mm is generally considered hypoplastic. The prevalence of portal vein hypoplasia in the setting of biliary atresia has been reported to be up to 26% [10].

### *Infradiaphragmatic total anomalous pulmonary venous return (TAVPVR)*

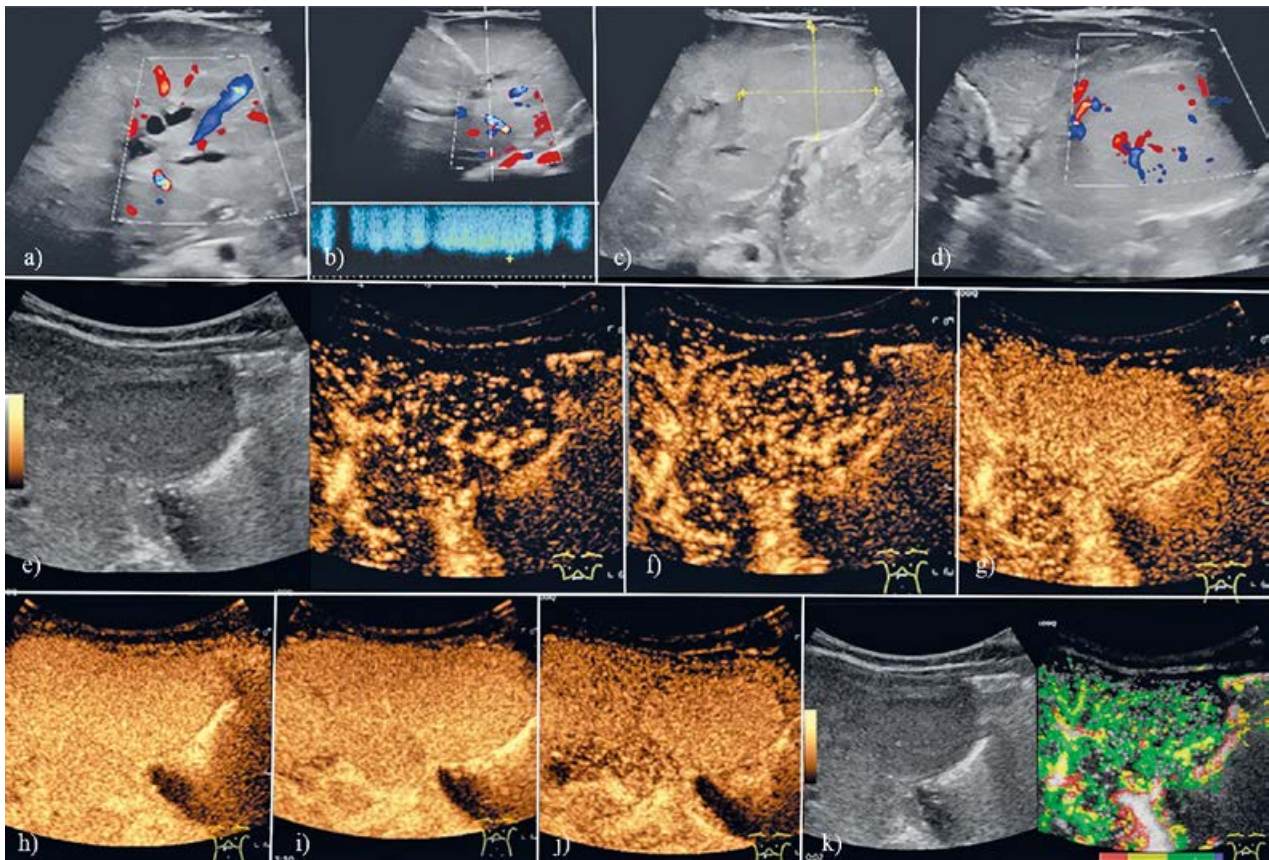
Total anomalous pulmonary venous return is a congenital heart malformation in which the pulmonary veins do not open into the left atrium and instead drain through an anomalous vein into the right heart, resulting in a left-to-right shunt. Types III and IV of these anomalies are tangential to the liver. The anomalous vein may drain into the superior vena cava (supracardiac or type I), coronary sinus (cardiac or type II), or IVC or portal vein below the diaphragm (infracardiac or type III); alternatively, it could drain into a mixture of the above (type IV). The anomalous vein typically drains into the portal vein (in about two-thirds of the cases) or the IVC. Venous obstruction at the level of the diaphragm is one of the criteria for -type-III TAPVR [10,12].

### *Congenital portosystemic shunts (CPS)*

Congenital portosystemic shunts are abnormal communications between the portal venous and the systemic venous system and portal vein atresia or dysplasia. Abernethy malformation types I and II with extrahepatic CPS is further discussed.

### *Patent ductus venosus Arantii*

Patent ductus venosus (PDV) is characterized by an intrahepatic shunt from the proximal part of the left portal branch to the terminal part of the left hepatic vein and located in the depth of the Arantius sulcus between the left and caudate lobes of the liver [13] (fig 1). The occluded ductus venosus passes into the ligamentum venosum, which joins the ligamentum teres. In the adult liver, it runs within the fissure between the anatomical left and right lobes and extends posteriorly into the in-



**Fig 1.** Bile duct atresia, choledochal cyst Todani I in a 3-month-old girl. An operation according to Kasai has already been performed. There is a patent foramen ovale, a patent ductus venosus Arantii, and no evidence of portal venous flow proximal to the sinister ramus principalis. There is a focal liver lesion in the left lobe of the liver. Ultrasonography shows a saccularly dilated segmental bile duct branches in the 2nd and 3rd liver segment (a). A patent ductus venosus Arantii with high flow velocity is shown (b). Focal liver lesion (FLL) in the left lobe of the liver in B-mode (c); FLL in the left lobe of the liver; duplex ultrasonography shows numerous vessels (d). CEUS: first vascular signals appear centrally, no “spoke-wheel” (e, f); homogeneous hyperenhancement in the arterial phase (g), portal venous phase (h) and in the late phase after >2 min (i) and more than 3 min (j). Parametric imaging with the first vessel signal in the center (red) (k). Late phase arterial hyperenhancement is a benignity criterion. The presence of a telangiectatic FNH is assumed in the result of the CEUS examination. A histological confirmation was not performed.

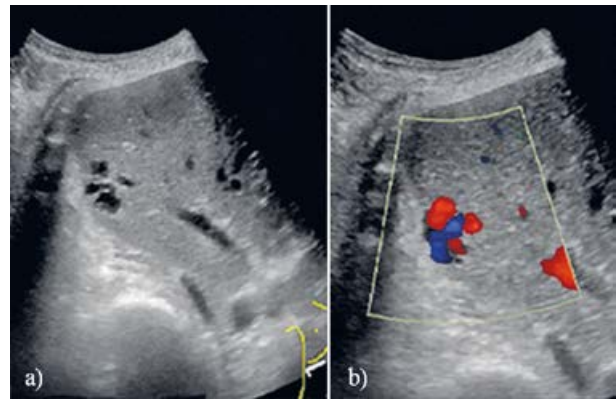


ferior vena cava. During fetal development, the venous duct connects the umbilical vein and the inferior vena cava. This allows blood from the umbilical vein to reach the left atrium via the inferior vena cava and the foramen ovale, bypassing the portal system. The ductus venosus closes after birth. Occlusion of the umbilical vein causes an abrupt drop in blood flow and functional occlusion of the ductus venosus Arantii. Other factors include changes in cardiac pressure and a decrease in endogenous prostaglandins, which can occur from within minutes to up to 37 days after birth [14].

Postnatally, the fetal shunts (ductus venosus, ductus arteriosus, and foramen ovale) close at different intervals. The ductus venosus is normally open for much longer than the ductus arteriosus [15,16]. The ductus venosus closes on day 3 in 12% of all healthy newborns, before day 7 in 76%, and before day 18 in all infants [15]. Among preterm infants, the ductus venosus closes by day 3 in only 9%, by day 8 in 40%, and by day 18 in 88%; all are closed by day 37, significantly later than in healthy newborns. The ductus venosus exhibits delayed closure in preterm infants, with no significant correlation with the closure of the ductus arteriosus or the condition of the infant. The color and pulsed Doppler flow signals in the ductus venosus reveal a typical cephalic biphasic waveform directed from the portal sinus into the inferior caval vein, similar to the velocity signals found in term infants. The signals become less biphasic and start to resemble continuous shunt signals or become monophasic over time [16].

An increasing pulsatile pattern and reversed flow velocity (triphasic flow) in the ductus venosus has been observed in infants with primary pulmonary hypertension and congenital heart defects with increased right atrial pressure [17]. The Doppler waveforms in the ductus venosus thus display different diagnostic relevance; the monophasic flow curve in the ductus venosus is regarded not only as an expression of functional obstruction but also in connection with pre-existing liver cirrhosis (i.e., hemochromatosis) in newborns. The biphasic flow curve is an expression of immature physiological systems, while the triphasic flow curve is the result of increased right atrial pressure due to congestive heart failure [14].

Prolonged patency or patent ductus venosus has been observed not only in preterm births but also in congenital heart disease (atrial septal defect and tricuspid regurgitation), pulmonary hypertension, hydrops fetalis, multiple coronary fistulas, hypoplastic right hepatoportal systems, tumor-like lesions of the liver, liver cirrhosis and fatty infiltration of the liver, and chromosomal abnormalities including Down's syndrome [14]. A familial occurrence in three brothers without known consanguinity has been



**Fig 2.** Intrahepatic portosystemic shunt (incidental finding) in a 89 y/o female with fever, dyspnea and pneumonia. Pancytopenia, agranulocytosis secondary to acute myeloid leukemia but no hepatic encephalopathy. On B-mode ultrasound, there was a polycyclic cystic lesion in the periphery of the right liver lobe (a). Doppler ultrasound showed non-pulsatile flow between a portal vein and hepatic vein branch (b). This was classified as an intrahepatic portosystemic shunt (Type III in the classification from Park 1990). This third type consists of peripheral portal and hepatic veins connecting through an aneurysm. The patient died from complications of acute myeloid leukemia.

described [17]. Clinical manifestations include galactosemia, hypoxemia, liver dysfunction, and encephalopathy. Development of encephalopathy depends on the shunt volume via the patent ductus venosus [18].

Park et al described four different morphological types in a classification of intrahepatic portosystemic shunts. The first and most common is a single large tube of constant diameter that connects the right portal vein to the inferior vena cava. The second type is a localized peripheral shunt in which single or multiple communications are found between the peripheral branches of portal and hepatic veins in one hepatic segment. The third type is aneurysmal: the peripheral portal and hepatic veins are connected through an aneurysm (fig 2). The fourth type exhibits diffuse, multiple communications between the peripheral portal and hepatic veins in both lobes [18,19]. The open ductus venosus is not specified in this classification.

A patent ductus venosus is detectable through Doppler sonography as a vascular, tubular structure in the left lobe of the liver, continuing from the left portal vein to the inferior vena cava in the location of hepatic vein confluence with the inferior vena cava [20]. In a total of 25579 patients without a history of abdominal trauma or operations, liver biopsy, hereditary hemorrhagic telangiectasia, Budd-Chiari syndrome, focal nodular hyperplasia (FNH), chronic hepatitis, cirrhosis, or hepatic malignancy, 6 (0.0235%) exhibited evidence of spontaneous intrahepatic PSVS in color Doppler sonography. Three

each were classified as types 1 and 3 according to Park et al's classification system. A PDV was not specified, indicating the rarity of the disease in adults [19,21].

An example of PDV described was significant dilatation of the left portal vein and a shunt of the left portal vein into the middle hepatic vein, which was considered a cystic dilatation without any turbulent flow [22]. A PDV between the anterior segmental branch of the portal vein and the middle hepatic vein has been reported [18]. Diminished small portal branches, notable attenuation of the main portal vein and collateral vessel within the liver to the inferior vena cava can be observed in US and Doppler sonography [17]. A reported case involves the co-occurrence of PDV with FNH, similar to the accumulation of FNH in Abernethy malformation [17,23]. The gold standard for diagnosis is angiography. Treatments for PDV remain controversial, and options include conservative management and surgical interventions such as coil embolization, Teflon banding, ligation, and liver transplantation [22].

### **Abernethy malformation (and FNH)**

Congenital portosystemic shunts (CPSS) are anomalies resulting in complete or partial diversion of the portal blood into systemic circulation. They were first described in 1793 by John Abernethy, who discovered a portal venous malformation during the postmortem examination of a 10-month-old girl. This malformation was subsequently named after him, and it consisted of a congenital extrahepatic portosystemic shunt (CEPS) [24]. Abernethy malformation is a very rare congenital vascular condition that comprises a number of anomalies: CPSS, liver nodules or tumors, and congenital heart disease as well as congenital diseases of other organs. It has countless clinical presentations, from being completely asymptomatic to causing hepatic carcinoma, neonatal cholestasis, hypergalactosemia, hepatic encephalopathy, severe pulmonary hypertension, and diffuse pulmonary arteriovenous malformation [25]. Most patients with Abernethy malformation are female and over 18 years of age at the time of diagnosis [26].

A review investigated 310 reported cases in 2019 [27]. There are different, complementary classifications of CPSSs. Morgan and Superina define complete portosystemic shunts not perfusing the liver via the portal vein as type I and partial shunts with minimal portal perfusion to the liver as type II [28].

Currently, CPSSs can be divided into four anatomic types [13,29]:

**Type I:** An extrahepatic end-to-side shunt without any detectable flow into the intrahepatic portal system,

apparently with absent intrahepatic portal branches. Type I can be further subclassified into types IA and IB based on the course of the splenic and mesenteric veins [28,30]:

**Type IA:** The splenic vein (SV) and superior mesenteric vein (SMV) are draining separately into a systemic vein such as the inferior vena cava (IVC) or a renal vein.

**Type IB:** The SV and SMV both drain into a systemic vein after merging into a common trunk. The confluence trunk of both veins usually drains into the suprarenal or suprahepatic IVC. Alternatively, it may flow into the hepatic vein, right atrium, iliac vein, or renal vein. Type IB is more common than IA (65.4% versus 30.8%)[30]. A 2015 report proposes a different classification system based on the visualization of the intrahepatic portal system architecture during angiography using a shunt occlusion test. The test demonstrates that almost every case diagnosed with a type-I CPSS exhibits a visible intrahepatic portal system. In addition, CPSSs can be classified into three types depending on the severity of the hypoplasia of the intrahepatic portal system: mild, moderate, and severe. This information has important therapeutic implications on whether the portal vasculature will accept portal flow after shunt occlusion [31].

**Type II:** An extrahepatic, either side-to-side or H-type shunt with some preserved intrahepatic portal flow. In type-II shunts, the intrahepatic portal vein is intact but hypoplastic, and some of the portal blood is diverted into a systemic vein (usually the IVC). Lautz et al subclassifies type II according to the origin of the shunt as follows: type 2a, which involves the right or left portal vein branch (PVB) (including patent ductus venosus); type 2b, with the shunt arising from the main PV at bifurcation or splenomesenteric confluence; and type 2c, which involves the SMV, SV, or gastric vein [32]. While type-I malformation is predominantly described in females, type II displays no gender predilection in its prevalence [33].

**Type III (intrahepatic type):** Intrahepatic shunt(s) of any configuration except persistent ductus venosus. Type III includes all other intrahepatic shunts that do not correspond to the persistent ductus venosus (PDV). These include, for example, shunts between the left branch of the portal vein and the left or middle hepatic vein.

**Type IV:** Persistent ductus venosus, characterized as an intrahepatic shunt from the proximal part of the left portal branch to the terminal part of the left hepatic vein and located in the depth of the Arantius sulcus between the left and caudate lobes of the liver [13,29].

The congenital extrahepatic shunt can also be subdivided according to the draining vessel [34]. Portal flow is classified as type A when it is directed into the IVC, type B into the renal vein, and type C into the iliac vein via

the mesenteric vein. In this “clinical classification,” the prevalence of cardiac anomalies in patients with type-A portal blood flow is slightly higher than in other shunt types. Lower gastrointestinal bleeding is considerably more common in type-C patients. The prevalence of portosystemic encephalopathy is higher among type-A and type-B sufferers and very rare among type-C patients. In addition to the absence of the portal vein, nodular liver lesions can be observed in almost half (45.5%) of the reported cases [26]. Compensatory increase in hepatic arterial blood flow as a result of the portal vein agenesis and absence of portal blood flow can be considered one cause of nodular liver lesions in Abernethy malformation. Systemic shunting of the visceral venous return may lead to abnormal development, malfunction, and regeneration of the liver, secondary to the absence of portal hepatotropic factors, resulting in the development of hepatic lesions [26,35]. Most of these lesions are characterized as benign, such as FNH (37% of the cases). Other types of reported lesions include nodular regenerated hyperplasia (16%), hepatoblastoma (4.1%), hepatic adenoma (10%), hepatocellular carcinoma (27%), and cirrhosis (6%) [26]. The coexistence of hemangiomas and hepatocellular cholangiocarcinomas have also been reported [27].

FNH is the most common hepatic tumor in patients with congenital absence of the portal vein. The occurrence of multiple FNHs have been described, along with the simultaneous presence of classic and telangiectatic FNH, or FNH and other liver tumors such as HCC and adenoma. According to the MRI findings, Zhang et al suspect an increased incidence of the telangiectatic variant of FNH [30]. Several known associations between primary liver disease and concomitant congenital cardiac defects have been identified. Congenital cardiac diseases, including the most common ventricular septal defects, atrial septal defect, open foramen ovale, and patent ductus arteriosus, are frequently observed concurrently with congenital absence of the portal vein (CAPV). Congenital stenosis of the aortic valve and pulmonary artery valve are also observed in a number of patients with CAPV. Concomitant atrial and ventricular septal defects associated with CAPV may be attributed to a congenital adaptive change that occurs during development from the embryonic stage and compensates for the congestive effects of portal venous aplasia. Dextrocardia or mesocardia and tetralogy of Fallot have been sporadically reported [26,27,36].

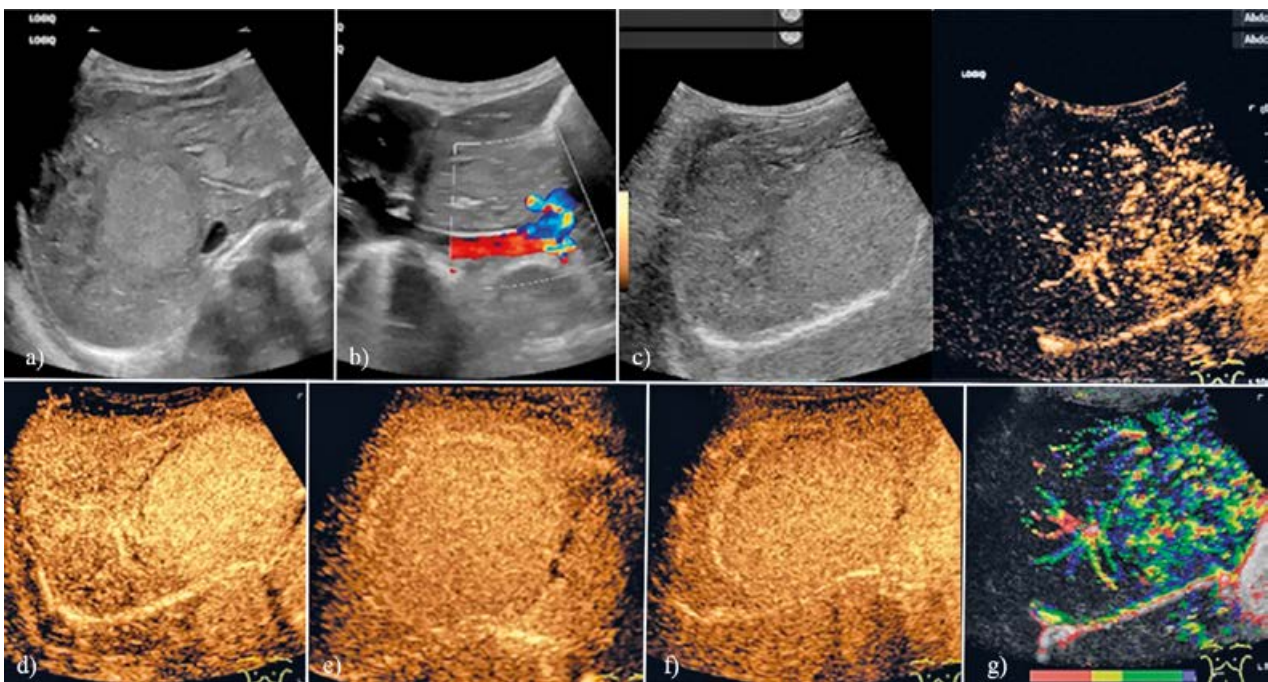
However, it has also been hypothesized that systemic shunting of portal venous flow can adversely affect cardiac function [37]. In addition to the aforementioned congenital cardiac diseases, other types of dysplasia involve the kidneys and urethra (e.g., cystic kidney dys-

plasia, ureteropelvic obstruction, crossed renal ectopia with vesicoureteral reflux, renal agenesis, hydronephrosis, and varicocele), spleen (e.g., polysplenia), bone (e.g., scoliosis, hemivertebrae, shortened fifth fingers and toes, hypoplasia of the thumb, absence of the first metacarpophalangeal complex, polydactyly, arachnodactyly, clinodactyly, sacral anomalies, facial dysmorphism, dolichocephalic, tarsal synostosis, clavicle agenesis, hip dysplasia, scoliosis, and hemivertebrae), arteries (e.g., aortic coarctation, double IVC, agenesis or stenosis of the IVC, azygos/hemiazygos continuation of the IVC, 2 splenic veins, double aortic arch, pulmonary artery stenosis, artery aneurysm, and pulmonary artery stenosis), bile duct (e.g., congenital choledochal cyst, Caroli disease, biliary atresia, congenital hepatic fibrosis, and intrahepatic gallbladder), or nervous system and endocrine glands. Bronchopulmonary malformations include bronchomalacia, bronchial stenosis, laryngomalacia, tracheal diverticulum, and lobar pulmonary sequestration. In addition, a number of patients are affected by genetic diseases such as Turner’s syndrome, Goldenhar’s syndrome (oculo-auriculo-vertebral dysplasia), Down’s syndrome, Costello’s syndrome, Trisomy 8, Ataxia-telangiectasia syndrome, Holt–Oram syndrome, Noonan syndrome, Klippel–Trenaunay–Weber syndrome, and Adams–Oliver syndrome [26,27].

Diagnostic evaluation usually involves the use of multiple imaging modalities. Although the initial suspicion always arises from an abnormal US scan of the abdomen, a high index of suspicion on the part of the person performing the scan is required. Doppler US allows for a quality study of all the vascular components of the liver and of their anatomic variants. Ultrasound delineation of the anatomy of the spleno-mesenteric venous system, portal venous trunk, and its main branches can raise suspicion of CEPS in cases of absence or hypoplasia of the PV, missing intrahepatic portal signals, and evidence of spontaneous porto-systemic shunts. Furthermore, it indicates compensatory hypertrophy of the hepatic artery and the presence of singular or multiple nodular changes in the liver [27,38].

The published case reports of FNH in congenital portosystemic shunts have been diagnosed by US, duplex, contrast CT, and MRI. US plays a role in the primary diagnosis and imaging of vascular changes [25,27,30,39–42]. However, there have been no published cases with CEUS, hence the behavior of FNH in congenital portal venous shunts is unclear. Hypertrophy of the common hepatic artery is typical. The behavior of FNH in the portal venous and the late phases, in the absence of portal venous flow owing to the shunt is unclear. FNH is usually hyperenhancing in the portal venous and late phases.





**Fig 3.** 1 y 10 month/male. Abernethy malformation, extrahepatic portocaval shunt and two focal liver lesions (59x53 mm and 10 mm). Patent foramen ovale, ventricular septum defect. Two hyperechoic focal liver lesions are visible in B-mode. Instead of intrahepatic portal branches, sabre sheath-like echoic changes are seen in the course of the liver segment vessels (a). The portocaval shunt is seen distal to the venous confluence at the hepatic hilum to the inferior vena cava (b). In CEUS, the larger hepatic lesion is hyperenhanced in the arterial phase. Several smaller, branching vessels present early arterially in the lesion (c). The lesion is homogeneously hyperenhanced in the arterial phase (d). The lesion remains hyperenhanced in the portal venous phase (e) and late phase (f). The parametric image shows early arterial multiple vessels in the liver lesion (red) (g). Hyperenhancement in the late phase is sign of a benign liver lesion. The presence of a FNH of the telangiectatic type is favoured, but not confirmed histologically.

In the absence of portal venous flow, FNH may show washout, and differentiation from malignant lesions becomes more difficult. Ponziani et al, following the EF-SUMB guidelines, recommends CEUS with reference to the typical contrast behavior of benign hepatic masses. However, there is no data in the literature on how these lesions behave on CEUS under conditions of absence of portal venous vascularization in the liver [27]. In our case of FNH in Abernethy malformation (fig 3), the portal venous and late phase showed hyperenhancement relative to the surrounding liver parenchyma. It must be noted that there is no histological confirmation.

The type of CAPV and simultaneous presence of congenital anomalies are the key factors in determining the severity of a patient's pathogenetic condition and the course of the disease. Type-I patients are typically referred for liver transplantation, whereas type-II shunts are amenable to endovascular treatment [43-45].

### Malformations, Osler disease

Hereditary hemorrhagic telangiectasia (HHT), also known as Osler-Weber-Rendu disease, is an autosomal

dominant disorder characterized by multiple mucocutaneous telangiectasias. These telangiectasias represent small arterio-venous malformations (AVMs), direct connections between the arterioles and venules bypassing the capillary beds that tend to bleed, causing patients significant amounts of distress in their daily lives. Problems associated with HHT include iron deficiency anemia as well as hematological, neurological, pulmonary, skin, and gastrointestinal tract symptoms. There are 2 main types of HHT, both caused by heterozygous mutations. The first type, HHT1, involves a mutation in endoglin (ENG). These patients, especially women, are at a higher risk of getting pulmonary and cerebral AVMs. Meanwhile, HHT2 involves a mutation in activin A receptor-like type 1 (ACVRL1), also known as ALK1, and patients with HHT2 have a higher risk of getting liver AVMs. Endoglin comprises about 61% of the mutations known to cause HHT, and ACVRL1 comprises about 37%. Mutations in growth differentiation factor 2 (GDF2) have also been observed. This gene encodes the protein that binds to endoglin and ACVRL1. Lastly, there are cases of mutations in SMAD4, which encodes a protein that transmits signals from the transforming growth factor beta (TGF- $\beta$ )

receptor. This mutation only comprises about 2% of cases. Patients with this gene mutation suffer from juvenile gastrointestinal (GI) polyposis and HHT [46,47].

The prevalence of HHT in Europe is 1.5 to 2 persons per 10,000, although some sources claim a higher number due to variable penetrance and the fact that the symptoms do not appear until later in adulthood. The disease has a higher prevalence in certain populations, such as the Afro-Caribbean residents of Curacao and Bonaire [48]. In many cases, clinical symptoms are limited to nasal bleeding, which occurs in more than 90% of patients. Epistaxis usually begins in childhood or adolescence at a mean age of 12 years, while telangiectasias do not tend to appear until after puberty and may not occur until adulthood. The latter are typically present on the face, lips, tongue, palms, and fingers, including the periungual area and the nail bed. Gastrointestinal bleeding is the most common symptom after epistaxis and occurs in approximately 13–30% of the cases, most commonly beginning after 50 years of age.

Patients with HHT may have multiple AVMs throughout the body. However, the most important ones for which clinicians should screen their patients are in the brain, lungs, GI tract, and liver. [49].

Diagnosis of HHT is considered if at least 3 of the 4 diagnostic criteria are met: 1) spontaneous and recurrent epistaxis; 2) multiple mucocutaneous telangiectasias at characteristic sites such as the lips, oral cavity, fingers, and nose; 3) visceral involvement, such as GI telangiectasia, pulmonary arterio venous malformations (AVMs), hepatic, and cerebral and spinal AVMs; and 4) a first-degree relative with HHT [50].

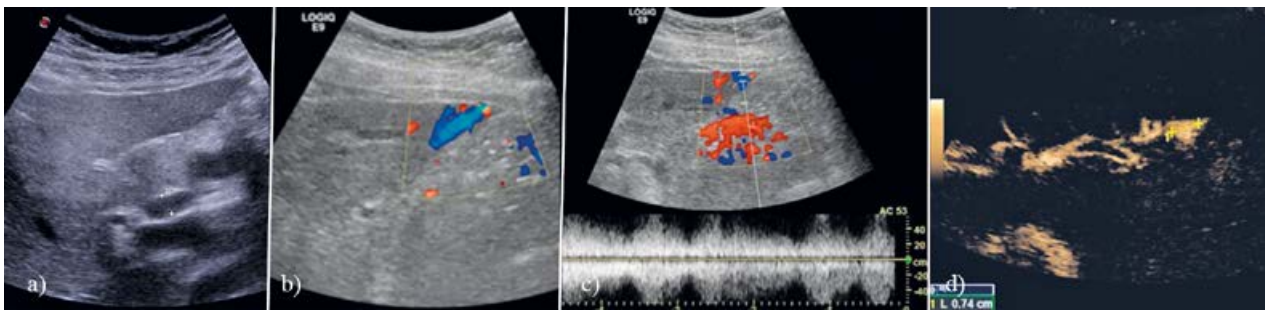
Hepatic vascular malformations are common (30–80% of all cases); liver involvement occurs most often in females around 48 years old and patients with the HHT2 genotype [51]. Mortality in HHT patients is closely linked to SMAD4 mutation and to chronic anemia, gastrointestinal bleeding, and symptomatic liver involvement [52]. Symptoms depend on the severity and type of shunting [53]: arteriosystemic shunting leads to manifestations of high-output cardiac failure and atrial fibrillation, and arteriportal shunting leads to portal hypertension and biliary disease, including ischemic cholangitis and bile duct necrosis. Shunts between portal and hepatic veins may increase the risk of portosystemic encephalopathy. A rare clinical manifestation is abdominal angina due to a steal phenomenon caused by the high hepatic artery flow volume [54,55]. The largest study on the natural history of patients with hepatic involvement in HHT reported complications and mortality related to hepatic AVMs in a follow-up period of median 44 months (range 12–181) involving 25.3% and 5.23% of patients, respectively [55].

Using multislice CT, Memeo et al demonstrated that the liver is affected in 41–78% of patients with HHT. In most of these patients, there were no clinical symptoms of liver disease [56]. Histological abnormalities of the blood vessels connected to the liver vary greatly in size from microscopic changes such as enlarged sinusoids to more complex large arteriovenous and portal venous shunts. The typically diffuse distribution, unusual in other vascular disorders, should always raise suspicion of underlying HHT [57].

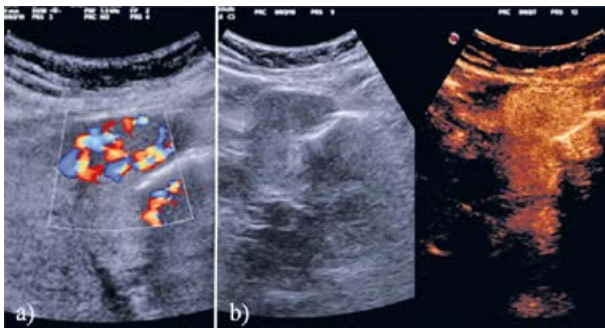
Imaging screening techniques include US, CT, and MRI [58]. B-mode and color-Doppler US evaluations are standard screening tests for liver AVMs in the initial workup of patients suspected of liver involvement [51,59]. These techniques can detect the location of large AVMs and evaluate the direction and magnitude of blood flow [60], in addition to screening for focal liver lesions, lesions of the biliary tree, and portal hypertension (splenomegaly, ascites, and portal varices). The US features of the disease include dilatation of the extrahepatic proper hepatic artery, defined as a diameter greater than 4–5 mm, owing to increased hepatic blood flow through arteriovenous fistulas, and dilated intrahepatic arterial branches which become more apparent with more advanced AVMs [53,61–63]. There is increased velocity within the proper hepatic artery, with some studies suggesting a peak flow velocity greater than 100 cm/s [61]; low arterial resistive index (RI <0.55); “arterialization” of the venous waveform; as well as dilatation and turbulent flow within the portal and hepatic veins. Porto-systemic shunts can be visualized as peripheral tubular structures with internal blood flow caused by arteriovenous, arteriportal, and portal venous fistulas, whereby color Doppler US reveals increased flow velocity, aliasing, and turbulence [53]. CEUS and newer techniques for microvascular evaluation may improve the detection of smaller arteriovenous shunts [64] (fig 4). The prevalence of solid focal liver lesions in patients with hepatic involvement in HHT is remarkable higher than is the general population with FNH and nodular regenerative hyperplasia most often observed [53,65] (fig 5), whereas hepatic hemangioma seems to be a rare co-occurrence (fig 6).

It is worth noting that the prevalence of FNH in patients with HHT is 2.9%, compared to 0.3% in the general population [53], as a result of an anomalous increase in blood flow to a specific portion of the liver parenchyma, which triggers a focal hyperplastic reaction in the liver cells [66–68]. Occasionally, patients with HHT do actually have cirrhosis (secondary to extensive necrotizing cholangitis), hepatocellular carcinoma, or hemobilia secondary to the rupture of AVMs in the biliary tree [69].





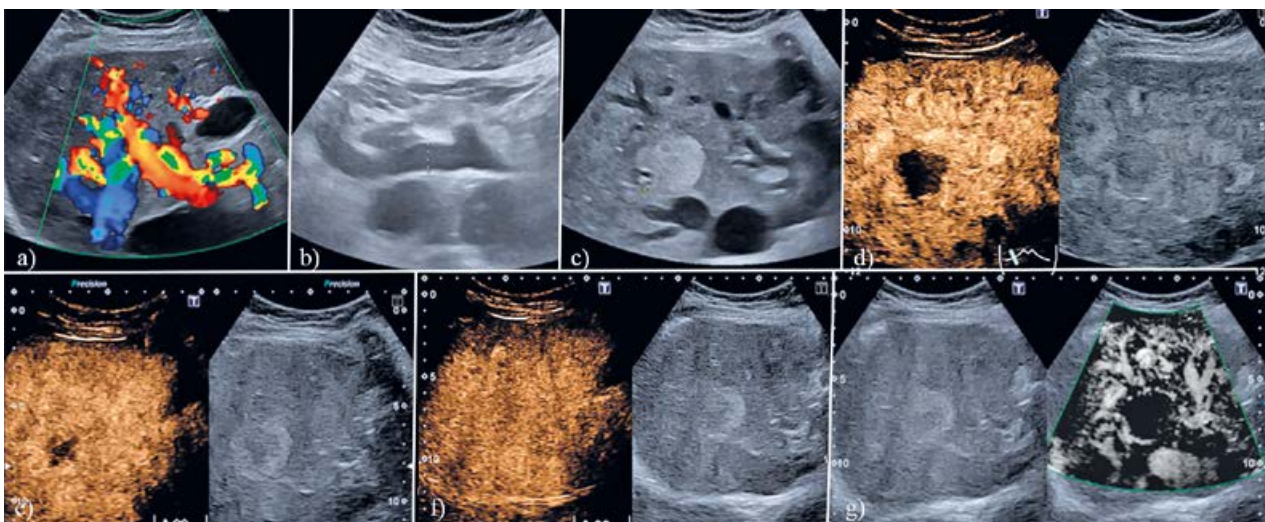
**Fig 4.** Dilated hepatic artery at the porta hepatis in a patient with Rendu-Osler syndrome (a). Peripheral A-V fistula is well detected on color-Doppler evaluation (b). Doppler showed a turbulent, low resistance flow typical of an a-v fistula (c). B-flow shows a dilated arterio-venous malformation (d). Explanation: The amplitude of scatterers in flowing blood is imaged by a subtraction mode of two to four vectors along one line. Noise reduction is gained by using digital encoded US pulses. Signal enhancement is performed by using a pulse compression method (coded excitation) [70].



**Fig 5.** Focal nodular hyperplasia in a hereditary hemorrhagic telangiectasia patient. Color-Doppler showed the “spoke-wheel” like appearance (a) and CEUS demonstrated arterial enhancement of the lesion (b).

### Conclusions

With a thorough and systematic examination of the hepatic artery, the portal vein and its branches and the hepatic veins using B-mode and Doppler sonography, it is possible to recognize normal variations, but also malformations. At the same time, liver parenchymal changes that are associated with these vascular changes are shown. Intrahepatic shunts can be detected. Decreased or absent portal venous flow usually leads to increased arterialization of the liver, causing a focal hyperplastic reaction of the liver cells. This favors the formation of nodules and development of tumors, typically focal hyperplastic neoplasia. CEUS is an important meth-



**Fig 6.** Incidental finding of hepatic Osler's disease in a 61 years old female. Colour Doppler showed numerous vessels with intrahepatic shunts of various types (a). The hepatic artery had a diameter of 11.5 mm (b, between markers). In liver segment VII, a homogeneous hyperechoic focal lesion was found with a diameter of 34 mm (c, between markers). CEUS characterized this as a cavernous hemangioma with nodular rim enhancement in the early arterial phase (d), progressive centripetal enhancement (iris phenomenon) in the portal-venous phase (e), which is to completion in the late phase (f). Microflow Imaging in the late phase shows the rich vasculature of the liver parenchyma, but no macrovessels within the focal lesion (g).

od for the diagnosis and differential diagnosis of these nodules.

**Conflict of interest:** none

## References

- Dietrich CF, Averkiou M, Nielsen MB, et al. How to perform Contrast-Enhanced Ultrasound (CEUS). *Ultrasound Int Open* 2018;4:E2-E15.
- Claudon M, Dietrich CF, Choi BI, et al. Guidelines and good clinical practice recommendations for Contrast Enhanced Ultrasound (CEUS) in the liver - update 2012: A WFUMB-EFSUMB initiative in cooperation with representatives of AFSUMB, AIUM, ASUM, FLAUS and ICUS. *Ultrasound Med Biol* 2013;39:187-210.
- Claudon M, Dietrich CF, Choi BI, et al. Guidelines and good clinical practice recommendations for contrast enhanced ultrasound (CEUS) in the liver--update 2012: a WFUMB-EFSUMB initiative in cooperation with representatives of AFSUMB, AIUM, ASUM, FLAUS and ICUS. *Ultraschall Med* 2013;34:11-29.
- Dietrich CF, Nolsoe CP, Barr RG, et al. Guidelines and Good Clinical Practice Recommendations for Contrast-Enhanced Ultrasound (CEUS) in the Liver-Update 2020 WFUMB in Cooperation with EFSUMB, AFSUMB, AIUM, and FLAUS. *Ultrasound Med Biol* 2020;46:2579-2604.
- Dietrich CF, Nolsoe CP, Barr RG, et al. Guidelines and Good Clinical Practice Recommendations for Contrast Enhanced Ultrasound (CEUS) in the Liver - Update 2020 - WFUMB in Cooperation with EFSUMB, AFSUMB, AIUM, and FLAUS. *Ultraschall Med* 2020;41:562-585.
- Sureka B, Patidar Y, Bansal K, Rajesh S, Agrawal N, Arora A. Portal vein variations in 1000 patients: surgical and radiological importance. *Br J Radiol* 2015;88:20150326.
- Sureka B, Sharma N, Khera PS, Garg PK, Yadav T. Hepatic vein variations in 500 patients: surgical and radiological significance. *Br J Radiol* 2019;92:20190487.
- Iqbal S, Iqbal R, Iqbal F. Surgical Implications of Portal Vein Variations and Liver Segmentations: A Recent Update. *J Clin Diagn Res* 2017;11:AE01-AE05.
- Choi TW, Chung JW, Kim HC, et al. Anatomic Variations of the Hepatic Artery in 5625 Patients. *Radiol Cardiothorac Imaging* 2021;3:e210007.
- Albers BK, Khanna G. Vascular Anomalies of the Pediatric Liver. *Radiographics* 2019;39:842-856.
- Papamichail M, Pizani M, Heaton N. Congenital portosystemic venous shunt. *Eur J Pediatr* 2018;177:285-294.
- Cirstoveanu C, Cinteza E, Marcu V, et al. Prostaglandin e1 on infradiaphragmatic type of total anomalous pulmonary venous connection - a case report. *Maedica (Bucur)* 2012;7:167-172.
- Blanc T, Guerin F, Franchi-Abella S, et al. Congenital portosystemic shunts in children: a new anatomical classification correlated with surgical strategy. *Ann Surg* 2014;260:188-198.
- Vade A, Lim-Dunham J, Iqbal N. Imaging of the ductus venosus in neonates: from patency to closure. *J Ultrasound Med* 2001;20:681-687.
- Fugelseth D, Lindemann R, Liestol K, Kiserud T, Langslet A. Ultrasonographic study of ductus venosus in healthy neonates. *Arch Dis Child Fetal Neonatal Ed* 1997;77:F131-134.
- Fugelseth D, Lindemann R, Liestol K, Kiserud T, Langslet A. Postnatal closure of ductus venosus in preterm infants < or = 32 weeks. An ultrasonographic study. *Early Hum Dev* 1998;53:163-169.
- Jacob S, Farr G, De Vun D, Takiff H, Mason A. Hepatic manifestations of familial patent ductus venosus in adults. *Gut* 1999;45:442-445.
- Saito M, Seo Y, Yano Y, et al. Successful treatment using coil embolization of a symptomatic intrahepatic portosystemic venous shunt developing through a patent ductus venosus in a noncirrhotic adult. *Intern Med* 2013;52:555-559.
- Park JH, Cha SH, Han JK, Han MC. Intrahepatic portosystemic venous shunt. *AJR Am J Roentgenol* 1990;155:527-528.
- Poeppelman RS, Tobias JD. Patent Ductus Venosus and Congenital Heart Disease: A Case Report and Review. *Cardiol Res* 2018;9:330-333.
- Lin ZY, Chen SC, Hsieh MY, Wang CW, Chuang WL, Wang LY. Incidence and clinical significance of spontaneous intrahepatic portosystemic venous shunts detected by sonography in adults without potential cause. *J Clin Ultrasound* 2006;34:22-26.
- Kamali L, Moradi M, Ebrahimian S, Masjedi Esfahani M, Jafarpishe MS. Patent ductus venosus in an infant with direct hyperbilirubinemia. *Clin Case Rep* 2019;7:1430-1434.
- Chandrasekharan R, Pullara SK, Thomas T, Kader NP, Moorthy S. Congenital intrahepatic portosystemic shunts: Imaging findings and endovascular management. *Indian J Radiol Imaging* 2016;26:92-94.
- Abernethy J. Account of Two Instances of Uncommon Formation in the Viscera of the Human Body: From the Philosophical Transactions of the Royal Society of London. *Med Facts Obs* 1797;7:100-108.
- Azad S, Arya A, Sitaraman R, Garg A. Abernethy malformation: Our experience from a tertiary cardiac care center and review of literature. *Ann Pediatr Cardiol* 2019;12:240-247.
- Hao Y, Hong X, Zhao X. Congenital absence of the portal vein associated with focal nodular hyperplasia of the liver and congenital heart disease (Abernethy malformation): A case report and literature review. *Oncol Lett* 2015;9:695-700.
- Ponziani FR, Faccia M, Zocco MA, et al. Congenital extrahepatic portosystemic shunt: description of four cases and review of the literature. *J Ultrasound* 2019;22:349-358.
- Morgan G, Superina R. Congenital absence of the portal vein: two cases and a proposed classification system for portosystemic vascular anomalies. *J Pediatr Surg* 1994;29:1239-1241.

29. De Vito C, Tyraskis A, Davenport M, Thompson R, Heaton N, Quaglia A. Histopathology of livers in patients with congenital portosystemic shunts (Abernethy malformation): a case series of 22 patients. *Virchows Arch* 2019;474:47-57.
30. Zhang K, Wang Q, Wang H, Ye H, Guo A, Duan W. Computed tomography and magnetic resonance imaging of multiple focal nodular hyperplasias of the liver with congenital absence of the portal vein in a Chinese girl: case report and review of the literature. *Eur J Med Res* 2014;19:63.
31. Kanazawa H, Nosaka S, Miyazaki O, et al. The classification based on intrahepatic portal system for congenital portosystemic shunts. *J Pediatr Surg* 2015;50:688-695.
32. Lautz TB, Tantemsapya N, Rowell E, Superina RA. Management and classification of type II congenital portosystemic shunts. *J Pediatr Surg* 2011;46:308-314.
33. Murray CP, Yoo SJ, Babyn PS. Congenital extrahepatic portosystemic shunts. *Pediatr Radiol* 2003;33:614-620.
34. Kobayashi N, Niwa T, Kirikoshi H, et al. Clinical classification of congenital extrahepatic portosystemic shunts. *Hepatol Res* 2010;40:585-593.
35. Banz V, Olliff S, Taniere P, Mayer D, Isaac J. Liver tumours in patients with Abernethy malformation. *ANZ J Surg* 2011;81:640-641.
36. Asrani SK, Asrani NS, Freese DK, et al. Congenital heart disease and the liver. *Hepatology* 2012;56:1160-1169.
37. Schmidt K, Held C, Franz N, et al. Cardiac dynamics in liver cirrhosis in the long-term follow-up after portosystemic shunting. *J Hepatol* 1991;13:170.
38. Pecek J, Fister P, Homan M. Abernethy syndrome in Slovenian children: Five case reports and review of literature. *World J Gastroenterol* 2020;26:5731-5744.
39. De Gaetano AM, Gui B, Macis G, Manfredi R, Di Stasi C. Congenital absence of the portal vein associated with focal nodular hyperplasia in the liver in an adult woman: imaging and review of the literature. *Abdom Imaging* 2004;29:455-459.
40. Tanaka Y, Takayanagi M, Shiratori Y, et al. Congenital absence of portal vein with multiple hyperplastic nodular lesions in the liver. *J Gastroenterol* 2003;38:288-294.
41. Turkbey B, Karcaaltincaba M, Demir H, Akcoren Z, Yuce A, Haliloglu M. Multiple hyperplastic nodules in the liver with congenital absence of portal vein: MRI findings. *Pediatr Radiol* 2006;36:445-448.
42. Kinjo T, Aoki H, Sunagawa H, Kinjo S, Muto Y. Congenital absence of the portal vein associated with focal nodular hyperplasia of the liver and congenital choledochal cyst: a case report. *J Pediatr Surg* 2001;36:622-625.
43. Lin Y, Li X, Li S, Ba H, Wang H, Zhu L. Treatment Option for Abernethy Malformation—Two Cases Report and Review of the Literature. *Front Pediatr* 2020;8:497447.
44. Mesquita RD, Sousa M, Vilaverde F, Cardoso R. Abernethy malformation: beware in cases of unexplained hepatic encephalopathy in adults—case report and review of the relevant literature. *BJR Case Rep* 2018;4:20170054.
45. Thirapattaraphan C, Treepongkaruna S, Ruangwattanapaisarn N, Sae-Guay S. Congenital extrahepatic portosystemic shunt (Abernethy malformation) treated with surgical shunt ligation: A case report and literature review. *Int J Surg Case Rep* 2020;66:4-7.
46. Jackson SB, Villano NP, Benhammou JN, Lewis M, Pisegna JR, Padua D. Gastrointestinal Manifestations of Hereditary Hemorrhagic Telangiectasia (HHT): A Systematic Review of the Literature. *Dig Dis Sci* 2017;62:2623-2630.
47. Morgan T, McDonald J, Anderson C, et al. Intracranial hemorrhage in infants and children with hereditary hemorrhagic telangiectasia (Osler-Weber-Rendu syndrome). *Pediatrics* 2002;109:E12.
48. Westermann CJ, Rosina AF, De Vries V, de Coteau PA. The prevalence and manifestations of hereditary hemorrhagic telangiectasia in the Afro-Caribbean population of the Netherlands Antilles: a family screening. *Am J Med Genet A* 2003;116A:324-328.
49. Guttmacher AE, Marchuk DA, White RI, Jr. Hereditary hemorrhagic telangiectasia. *N Engl J Med* 1995;333:918-924.
50. Shovlin CL, Guttmacher AE, Buscarini E, et al. Diagnostic criteria for hereditary hemorrhagic telangiectasia (Rendu-Osler-Weber syndrome). *Am J Med Genet* 2000;91:66-67.
51. Faughnan ME, Mager JJ, Hetts SW, et al. Second International Guidelines for the Diagnosis and Management of Hereditary Hemorrhagic Telangiectasia. *Ann Intern Med* 2020;173:989-1001.
52. Thompson KP, Nelson J, Kim H, et al. Predictors of mortality in patients with hereditary hemorrhagic telangiectasia. *Orphanet J Rare Dis* 2021;16:12.
53. Buscarini E, Danesino C, Olivieri C, et al. Doppler ultrasonographic grading of hepatic vascular malformations in hereditary hemorrhagic telangiectasia -- results of extensive screening. *Ultraschall Med* 2004;25:348-355.
54. Garcia-Tsao G, Korzenik JR, Young L, et al. Liver disease in patients with hereditary hemorrhagic telangiectasia. *N Engl J Med* 2000;343:931-936.
55. Buscarini E, Leandro G, Conte D, et al. Natural history and outcome of hepatic vascular malformations in a large cohort of patients with hereditary hemorrhagic teleangiectasia. *Dig Dis Sci* 2011;56:2166-2178.
56. Memeo M, Stabile Ianora AA, et al. Hepatic involvement in hereditary hemorrhagic telangiectasia: CT findings. *Abdom Imaging* 2004;29:211-220.
57. Govani FS, Shovlin CL. Hereditary haemorrhagic telangiectasia: a clinical and scientific review. *Eur J Hum Genet* 2009;17:860-871.
58. Buscarini E, Gandolfi S, Alicante S, Londoni C, Manfredi G. Liver involvement in hereditary hemorrhagic telangiectasia. *Abdom Radiol (NY)* 2018;43:1920-1930.
59. European Association for the Study of the Liver. Electronic address eee. EASL Clinical Practice Guidelines: Vascular diseases of the liver. *J Hepatol* 2016;64:179-202.
60. Schelker RC, Barreiros AP, Hart C, Herr W, Jung EM. Macro- and microcirculation patterns of intrahepatic blood flow changes in patients with hereditary hemorrhagic telangiectasia. *World J Gastroenterol* 2017;23:486-495.



61. Naganuma H, Ishida H, Kuroda H, Suzuki Y, Ogawa M. Hereditary hemorrhagic telangiectasia: how to efficiently detect hepatic abnormalities using ultrasonography. *J Med Ultrason* (2001) 2020;47:421-433.
62. Caselitz M, Bahr MJ, Bleck JS, et al. Sonographic criteria for the diagnosis of hepatic involvement in hereditary hemorrhagic telangiectasia (HHT). *Hepatology* 2003;37:1139-1146.
63. Ocran K, Rickes S, Heukamp I, Wermke W. Sonographic findings in hepatic involvement of hereditary haemorrhagic telangiectasia. *Ultraschall Med* 2004;25:191-194.
64. Oe Y, Orr L, Laifer-Narin S, et al. Contrast-enhanced sonography as a novel tool for assessment of vascular malformations. *J Angiogenesis Res* 2010;2:25.
65. Brenard R, Chapaux X, Deltenre P, et al. Large spectrum of liver vascular lesions including high prevalence of focal nodular hyperplasia in patients with hereditary haemorrhagic telangiectasia: the Belgian Registry based on 30 patients. *Eur J Gastroenterol Hepatol* 2010;22:1253-1259.
66. Draghi F, Presazzi A, Danesino GM, de Matthaecis N, Rappaccini GL, Danesino C. Hepatic sonography in patients with hereditary hemorrhagic telangiectasia hospitalized for epistaxis. *J Ultrasound* 2012;15:164-170.
67. Schelker RC, Barreiros AP, Hart C, Herr W, Jung EM. Macro- and microcirculation patterns of intrahepatic blood flow changes in patients with hereditary hemorrhagic telangiectasia. *World J Gastroenterol* 2017;23:486-495.
68. Schelker RC, Andorfer K, Putz F, Herr W, Jung EM. Identification of two distinct hereditary hemorrhagic telangiectasia patient subsets with different hepatic perfusion properties by combination of contrast-enhanced ultrasound (CEUS) with perfusion imaging quantification. *PLoS One* 2019;14:e0215178.
69. Carette MF, Nedelcu C, Tassart M, Grange JD, Wislez M, Khalil A. Imaging of hereditary hemorrhagic telangiectasia. *Cardiovasc Intervent Radiol* 2009;32:745-757.
70. Weskott HP. [B-flow—a new method for detecting blood flow]. *Ultraschall Med* 2000;21:59-65.